



**PATIENT**

Luna Uran

**SPECIES**

Canine

**BREED**

Maltese

**SEX**

Female Spayed

**AGE**

15 years

**WEIGHT**

7.1lbs

**PRESENTING CLINICAL SIGNS**

History: History hypothyroidism (treated with Soloxine 0.1 mg q12h. Grade III-IV/VI systolic murmur; no clinical signs. Started Pimobendan 5mg, 1/2-tab q12h.

**ECHOCARDIOGRAM FINDINGS**

2D, m-mode, color flow and Doppler imaging is available.

**Left ventricle:** The LV diameter is increased with hyperdynamic function. LV wall thicknesses are normal.

**Left atrium:** The left atrium is severely dilated.

**Mitral valve:** The mitral valve is diffusely thickened with prolapse into the left atrial lumen. Severe eccentric mitral regurgitation with a normal velocity.

**Aortic valve/Aorta:** The aortic valve appears thickened with borderline increased outflow velocity; laminar flow. Mild to moderate aortic insufficiency.

**Right ventricle:** Mild RV enlargement.

**Right atrium:** Mild RA enlargement.

**Tricuspid valve:** The tricuspid valve appears mildly thickened with septal prolapse and moderate tricuspid regurgitation; normal velocity.

**Pulmonic valve/Pulmonary artery:** The pulmonic valve is normal in morphology and mobility. No pulmonic insufficiency. Normal RVOT velocity; laminar flow.

**Pericardium/other:** No pericardial or pleural effusion noted. No obvious cardiac masses.

**INTERPRETED BY**

Maggie Machen  
Lamy, DVM  
DACVIM (Cardiology)

**2-Dimensional Measurements**

Ao diam (cm)	1.4
LA diam (cm)	3.1
LA:Ao (Swe)	2.4
IVS thickness (cm)	0.5
LVID diastole (cm)	3.0
PW thickness (cm)	0.5
LVID systole (cm)	1.6
FS (%)	46

**Doppler Measurements**

PV Vmax (m/s)	0.62
AoV Vmax (m/s)	1.5
MR Vmax (m/s)	5.5
TR Vmax (m/s)	2.6
TR PG (mmHg)	28

**IMAGING PERFORMED BY**

Pamela Harrigan,  
RDCS

**HOSPITAL NAME**

East Boston Animal  
Hospital

**REFERRING VET**

Dr. Chopra

**INVOICE**

26087

**DATE**

8/29/22

**INTERPRETATION OF THE FINDINGS**

Chronic degenerative valve disease causing severe mitral and moderate tricuspid regurgitation. The LA is significantly dilated indicating an elevated risk for clinical signs going forward. TR is noted with no significant elevation in pulmonary pressures; however, there is mild right heart enlargement. Finally, an aortic leak is noted, and a baseline blood pressure is recommended. No additional concurrent issues are documented.

With this degree of left heart changes, the risk for spontaneous congestive heart failure is elevated and cardiac supportive medications are indicated as below. A weak diuretic (spironolactone) is included given high risk for decompensation in the future even with no reported symptoms. Assessment of progression in the future will help predict long term outcome, however prognosis is guarded at this stage (late B2). Unfortunately, the patient will always be at risk for recurrent CHF, development of arrhythmias/LA tear, syncope and/or sudden death in the future.



**PATIENT**

Luna Uran

**SPECIES**

Canine

**BREED**

Maltese

**SEX**

Female Spayed

**AGE**

15 years

**WEIGHT**

7.1lbs

**RECOMMENDATIONS**

- Administer Pimobendan 0.3mg/kg PO q12h.
- Institute ACE-I (benazepril or enalapril) 0.5mg/kg PO q12h.
- Institute spironolactone 1-2mg/kg PO q12h.
- Close monitoring for development of associated clinical signs (development of a cough, labored breathing, exercise intolerance or worsening collapse episodes) is recommended. Monitoring of sleeping breathing rates is recommended as the best way to screen for CHF at home.
- Omega fatty acid supplementation and mild salt restriction may be of some long-term benefit. Mild activity restriction is advised.
- Elective anesthesia is not advised, as there is high risk for complication. If necessary, cardiac protective drug choices (opioid/benzodiazepine premedication, propofol or alfaxalone induction, iso or sevoflurane gas) are recommended. Pre-oxygenate for 5-10 minutes prior to induction and recover in O2 cage. Monitor for arrhythmias, hypotension, and hypoxia both intra and post-operatively and intervene as necessary. Moderate IV fluid restriction is recommended to avoid fluid overload. Avoid heart rate stimulating drugs such as atropine unless clinically indicated.

**PLAN**

- A renal panel and BP is recommended in 1-2 weeks, then every 3-4 months lifelong.
- Recommend conservative monitoring with a recheck echocardiogram in 6 months, sooner if any development of clinical signs.

**INTERPRETED BY**

Maggie Machen  
 Lamy, DVM  
 DACVIM (Cardiology)

**IMAGING PERFORMED BY**

Pamela Harrigan,  
 RDCS

**HOSPITAL NAME**

East Boston Animal  
 Hospital

**REFERRING VET**

Dr. Chopra

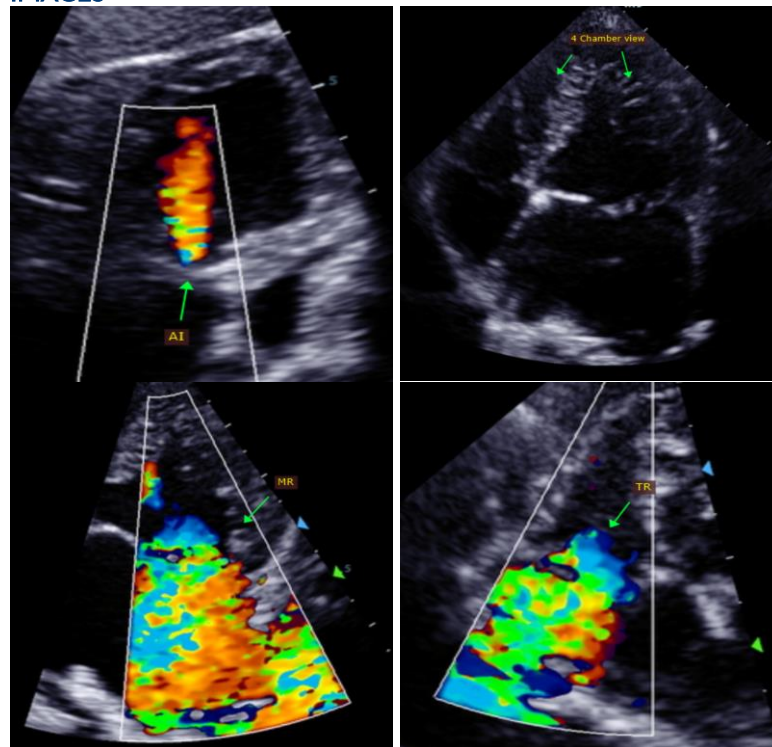
**INVOICE**

26087

**DATE**

8/29/22

**IMAGES**





**PATIENT**

Luna Uran

The information and recommendations provided are based on the images presented by the referring veterinarian. No evaluation can be communicated regarding pathology that was not visible in the image/video clips provided.

**SPECIES**

Canine

Thank you for this referral. This report was generated using transcription software, and minor dictation errors may be present. If the clinical or image interpretation does not parallel your findings or if I can be of any further assistance, please contact me.

**BREED**

Maltese

Maggie Machen Lamy, DVM  
Diplomate of the American College of Veterinary Internal Medicine (Cardiology)  
info@sonopath.com

**SEX**

Female Spayed

**AGE**

15 years

**WEIGHT**

7.1lbs

**INTERPRETED BY**

Maggie Machen  
Lamy, DVM  
DACVIM (Cardiology)

**IMAGING  
PERFORMED BY**

Pamela Harrigan,  
RDCS

**HOSPITAL NAME**

East Boston Animal  
Hospital

**REFERRING VET**

Dr. Chopra

**INVOICE**

26087

**DATE**

8/29/22